

Pulmonary Manifestations of Systemic Autoimmune Diseases

M. COJOCARU, MD, PhD^a; Inimioara Mihaela COJOCARU, MD, PhD^b;
Isabela SILOSI, MD, PhD^c; Camelia Doina VRABIE, MD, PhD^c

^a"Titu Maiorescu" University, Faculty of Medicine, Department of Physiology, Center for Rheumatic Diseases, Bucharest, Romania

^b"Carol Davila" University of Medicine and Pharmacy, Clinic of Neurology, Colentina Clinical Hospital, Bucharest, Romania

^c"University of Medicine and Pharmacy, Department of Immunology, Craiova, Romania

^d"Carol Davila" University of Medicine and Pharmacy, Clinical Hospital of Emergency "Sfantul Ioan", "Victor Babes" National Institute for Pathology and Biomedical Sciences, Bucharest, Romania

ABSTRACT

Systemic autoimmune diseases (SAD) are a heterogeneous group of immunologically mediated inflammatory disorders including multiorgan involvement. As expected in a multisystem disease, the entire pulmonary system is vulnerable to injury. Any of its compartments may be independently or simultaneously affected. It is difficult to assess the true prevalence of lung disease in cases of SAD. In this article, we will review the pulmonary manifestations caused by systemic lupus erythematosus, rheumatoid arthritis, systemic sclerosis, polymyositis/dermatomyositis, Sjögren's syndrome, mixed connective tissue disease, Wegener's granulomatosis, Churg-Strauss syndrome, Goodpasture's syndrome, and ankylosing spondylitis.

Keywords: systemic autoimmune diseases, pulmonary manifestations

INTRODUCTION

Immunologic lung diseases develop when the normal mechanisms of immune self-tolerance fail. Macrophages and lymphocytes are the key cells involved in the initiation and perpetuation of the acquired immune response in the lung. Macrophages serve as scavenger cells, ingesting and degrad-

ing the inhaled antigenic load. In addition, these cells serve as antigen-presenting cells for T lymphocytes. Relatively few lymphocytes are present in the normal lung parenchyma. However, after stimulation by the relevant antigen in the surrounding lymphoid tissues, lymphocytes specific for that antigen migrate to the lung and participate in the inflammatory response. Essentially all SAD appear to be depen-

Address for correspondence:

Manole Cojocaru, Str. Thomas Masaryk No. 5 Sector 2 Postal Code 020983. Bucharest, Romania
e-mail: manole.cojocaru@yahoo.com

dent on the inappropriate activation of autoreactive CD4 T cells as well as autoreactive B cells responsible for the pathogenic autoantibodies. Depending on the underlying autoimmune process, the pleura, pulmonary parenchyma, or airway may be predominantly affected. SAD are a heterogeneous group of diseases, which frequently involve the lungs. The pleuro-pulmonary manifestations of these diseases are diverse, affecting all anatomic locations of the respiratory tract (i.e. airways, alveoli, blood vessels, and pleura). Although pulmonary complications generally occur in patients with well established disease occasionally the lung involvement is the first manifestations of the autoimmune disorder. Further studies are therefore needed to better understand these conditions, and to develop more effective rational therapies (1,2).

Systemic lupus erythematosus

Viewed histologically, systemic lupus erythematosus (SLE) is characterized by some combination of inflammation and fibrosis, and the clinical phenotype is dictated by the relative contributions of each and the organs affected. Tissue injury appears to be mediated by characteristic autoantibody production, immune complex formation, and their organ-specific deposition. As expected in a multisystem disease, the entire pulmonary system is vulnerable to injury. Pulmonary involvement is frequent in SLE, and can affect the pleura, pulmonary vasculature, and parenchyma. The most common manifestation is unilateral or bilateral pleural effusion that frequently is associated with pericardial effusion. Pulmonary parenchymal abnormalities are also common. In most patients pneumonia has a bacterial pathogenesis in patients with SLE, opportunistic infections occur with increased frequency. Pulmonary hemorrhage is another manifestation, though less common. Pulmonary fibrosis is less common in SLE than in rheumatoid arthritis (RA) or systemic sclerosis (SSc). Fibrosis involved predominantly the lung periphery and lower lobes. Other manifestations of SLE are loss of lung volume related to diaphragmatic dysfunction, pulmonary edema. Acute lupus pneumonitis is an uncommon manifestation of SLE. Interstitial lung disease (ILD) and pulmonary hypertension (PH) may be seen in SLE, but are more common in other SAD such as SSc, dermatomyosi-

tis (DM), or overlap syndromes. An unusual syndrome referred to as shrinking lung syndrome has been described in SLE patients with progressive dyspnea. Acute episodes of reversible hypoxemia have also been described in patients with SLE (1-4)

Rheumatoid arthritis

There are several distinct patterns of pulmonary involvement that occur in patients with RA. Lung disease is a leading cause of death in RA, second only to infection. The pulmonary manifestations of RA were first described in 1948, when Ellman and Ball recognized diffuse pulmonary fibrosis in three patients with RA. Pulmonary complications of RA include pleural effusion, nodular lung disease, diffuse interstitial fibrosis, pulmonary vasculitis, alveolar hemorrhage, obstructive pulmonary disease, and infections. Pleural disease may be detected in almost half of RA patients at necropsy. The most common pulmonary manifestations of RA is pleural effusion. These effusions can be unilateral or bilateral, and persist for many months. Pleural effusions cause compromise of pulmonary function. Typically, the pleural fluid is exudative, with a low glucose and low complement levels. Rheumatoid nodules may be noted in the pulmonary parenchyma, either singly or in clusters. Pulmonary nodules in patients with RA were first described by Caplan in 1953. Pulmonary nodules can appear before, with, or after the onset of RA. Diffuse interstitial fibrosis initially is characterized by chronic inflammatory changes in the alveolar walls and the presence of large mononuclear cells in the alveolar spaces. Diffuse interstitial fibrosis occurs mostly in patients who have subcutaneous nodules. The prognosis for patients with RA who have interstitial fibrosis is poor. Pulmonary vasculitis, one of the least common pulmonary manifestations of RA is seen in patients with severe RA. Alveolar hemorrhage leads to hemoptysis, diffuse infiltrates, and anemia. Lung function tests of patients with RA-related airway obstruction show airflow obstruction. Several studies have shown that the peak respiratory flow rate is significantly reduced in patients with RA and airway obstruction. Patients with RA and lung lesions had a high incidence of bronchitis and bronchiectasis. Pulmonary manifestations of RA that are more likely to become symptomatic include ILD and pulmonary arte-

ritis. Pulmonary arthritis, which is rare, may cause PH and cor pulmonale. Pulmonary involvement in patients with RA may also result from the drugs used in therapy. In order to provide optimal treatment, physicians must always consider the possibility of pulmonary manifestations when evaluating patients with RA (1,2).

Systemic sclerosis (scleroderma)

Pulmonary disease may remain largely silent in SSc patients until organ damage is severe. Patients with SSc have restrictive lung disease from interstitial fibrosis. The fibrosis is thought to follow an inflammatory alveolitis, in which increased number of macrophages, neutrophils, lymphocytes, and eosinophils invade the lungs. The majority of patients with pulmonary fibrosis and SSc have a histological pattern of usual interstitial pneumonia. However, many cases have a pattern of non-specific interstitial pneumonitis. This lung inflammation can be detected by an increased percentage of neutrophils in bronchoalveolar fluids or lung biop-

sy, which identifies patients at greater risk for subsequent decline in lung function or death. There is an increased prevalence of lung cancer in patients with SSc, particularly in those with pulmonary fibrosis. Pathogenesis of pulmonary fibrosis is initiated by microvascular injury, which leads to endothelial cell damage and alveolar epithelial injury. This leads to activation of the coagulation cascade (Figure 1). Autoantibody expression is a predictor of internal organ involvement, particularly lung involvement. The presence of anti-topoisomerase antibodies (Scl-70) is strongly associated with development of significant ILD, while anti-centromere antibodies appear to be protective.

Further study into the cell types, mediators, and pathways involved in lung fibrosis is needed. These further studies may lead to a better understanding of lung fibrosis, and to the development of safer and more effective rational therapies. Pleural disease is not a common manifestation, but when present, it is usually accompanied by parenchymal disease. Patients with SSc present PH. It can be a devastating

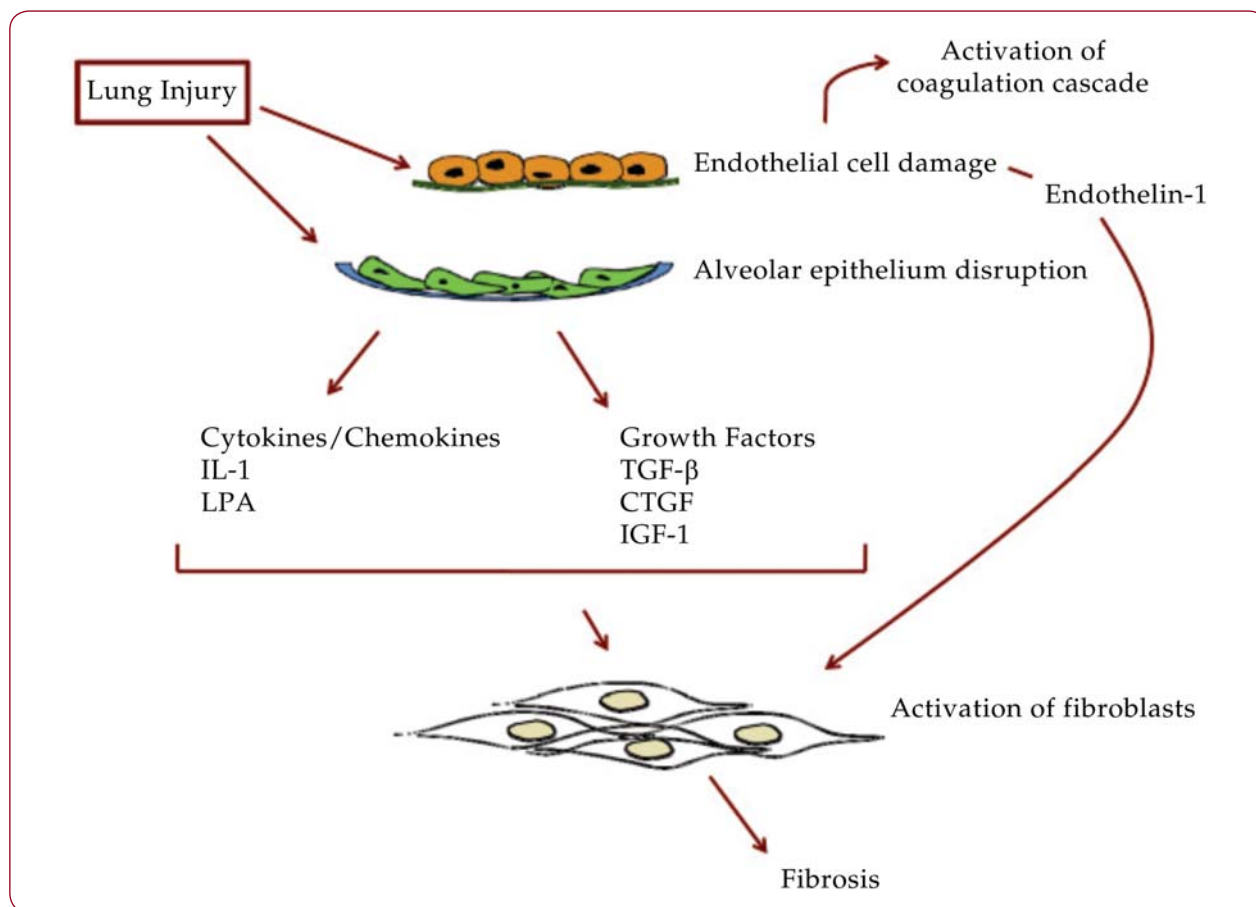


FIGURE 1. Mechanisms perpetuating pulmonary fibrosis (Castelino & Varga, 2010) (1)

consequence of severe interstitial fibrosis. Aspiration pneumonia occurs with increased frequency owing to esophageal dysfunction (1,2,5-8).

Polymyositis/dermatomyositis

Pulmonary complications in polymyositis (PM) and DM are important causes of morbidity and mortality and may overshadow the muscle involvement. Approximately 40% of patients with PM/DM have pulmonary involvement. As opposed to the other SAD, lung involvement in PM/DM does not primarily involve the airways or the pleura. The most common manifestation is aspiration pneumonia secondary to pharyngeal muscle weakness. Involvement of the diaphragm leads to diaphragmatic elevation, reduced lung volumes, and basilar atelectasis. Interstitial fibrosis involved the lung bases. The presence of ILD markedly influences the disease course in inflammatory myositis. The strongest predictive factor is the presence of autoantibodies to aminoacyl tRNA synthetase, most commonly anti-Jo-1. Other parenchymal abnormalities include bronchiolitis obliterans organizing pneumonia and diffuse alveolar damage (1,2,9,10).

Sjögren's syndrome

Involvement of exocrine glands in the upper respiratory tract frequently leads to dryness of the nasal passages and bronchi. Especially common respiratory problems are associated with mucous plug inspiration in the setting of an upper respiratory tract infection, resulting in increased tenacious secretions that cannot be adequately mobilized from the small airways. The most common manifestation associated with Sjögren syndrome (SSj) is pulmonary fibrosis. There is an increased prevalence of lymphocytic interstitial pneumonitis involving the lower lobes. Patients with SSj can also develop pleurisy (with or without effusion) and ILD with lymphoid interstitial pneumonitis (1,2,11,12).

Mixed connective tissue disease

Pulmonary involvement is a common complication of mixed connective tissue disease (MCTD). This SAD is defined as a generalized connective tissue disorder characterized by the presence of high titre anti-U1 ribonucleoprotein (U1-RNP) antibodies and antibodies against U1-70 kd small nuclear ribonucleopro-

tein (snRNP) in combination with clinical features commonly seen in SLE, SSc, and PM. Pulmonary impairment is not usually clinically evident early in the course of the disease. ILD, such as fibrosing alveolitis, as well as PH are rather serious pulmonary complications of MCTD. The prognosis of ILD may be better in MCTD than in SSc. The elevated levels of immune complexes (IC) and increased complement consumption indicated that IC-mediated alveolocapillary membrane damage and tissue injury might play a role in the pathogenesis of ILD in MCTD. Patients with MCTD have a reduced diffusing capacity for carbon monoxide, and evidence of restrictive abnormalities on pulmonary function tests (1,2,13,14).

Wegener's granulomatosis

Lung disease develops in most patients with Wegener's granulomatosis (WG). The clinical manifestations of WG are equally diverse, ranging from asymptomatic lung nodules to fulminant alveolar hemorrhage. WG may be associated with multiple nodules or masses with irregular margins that are frequently cavitated. Pleural effusions occur rarely. Mediastinal and hilar adenopathy are relatively uncommon. Localized or diffuse areas of air-space consolidation may be present. Involvement of the tracheal or bronchial walls usually consists of mucosal or submucosal granulomatous thickening. The infiltrates, which may wax and wane, are often misdiagnosed initially as pneumonia. Nodules are usually multiple and bilateral, and often result in cavitations (1,2).

Churg-Strauss syndrome

The lung is the most common organ involved; greater than 90% of Churg-Strauss syndrome (CSS) patients have histories of asthma. CSS is an allergic angiitis and granulomatous necrotizing vasculitis that occur almost exclusively in patients with asthma. Patients are typically asthmatic and present with eosinophilia, fever, and allergic rhinitis. The areas of consolidation may have a peripheral distribution and are often transient. Nodules may occur, but cavitation is rare. Pleural effusions are relatively uncommon. Other, less common manifestations included pulmonary nodules, interlobular septal thickening, and bronchial wall thickening. There are three phases of the CSS: prodromal phase, characterized by the presence of

allergic disease (typically asthma or allergic rhinitis), which may last from months to many years; eosinophilia/tissue infiltration phase, in which remarkably high peripheral eosinophilia may occur and tissue infiltration by eosinophils is observed in the lung, gastrointestinal tract, and other tissues; vasculitic phase, in which systemic necrotizing vasculitis afflicts a wide range of organs, ranging from the heart and lungs to peripheral nerves and skin. The diagnosis is sometimes unclear due to similarities with other vasculitides, such as WG (1,2).

Goodpasture's syndrome

In the majority of cases, the lung and renal involvement occur simultaneously. Goodpasture's syndrome is defined by a triad of diffuse pulmonary hemorrhage, glomerulonephritis, and circulating antiglomerular basement membrane antibodies. The clinical pulmonary presentation usually consists of cough, mild shortness of breath, hemoptysis, and hypoxia in young male patients. Goodpasture's syndrome is associated with extensive bilateral air-space consolidation. The cardinal pathogenic factor is autoantibody to a component of type IV collagen present in the capillary basement membranes of the lung and kidney. These autoantibodies are called antiglomerular basement membrane (anti-GBM) antibodies because glomerular antigens are normally used for their detection in immunoassays (1,2).

Ankylosing spondylitis

Abnormalities were found to be prevalent (50-85%) even in patients with early ankylosing spondylitis. Changes included apical fibrosis, ILD, emphysema, bronchiectasis and pleural thickening. In general, the changes were of mild degree. Spontaneous pneumothorax was reported to be a rare complication. Common associated abnormalities include apical bullae and cavitation, potentially mimicking tuberculosis. Restriction of the chest wall may result from fusion of the costovertebral joints (15, 16). □

CONCLUSIONS

In summary, SAD can cause a variety of pulmonary abnormalities that are influenced by the pathophysiologic characteristics of the underlying disease process. Pulmonary manifestations of SAD include pleural disease, pulmonary fibrosis (in the upper lobes), diaphragm weakness, aspiration pneumonia, bronchiolitis obliterans organizing pneumonia, bronchiolitis obliterans, and bronchiectasis. RA and SLE represent the most common immunological diseases that affect the pleural cavity. ILD is now increasingly recognized as a frequent and serious complication of systemic autoimmune diseases. □

COMPETING INTERESTS

The authors declare that they have no competing interests.

REFERENCES

1. **Castelino FV, Varga J.** – Interstitial lung disease in connective tissue diseases: evolving concepts of pathogenesis and management. *Arthritis Research & Therapy* 2010; 12: 213. doi:10.1186/ar3097.
2. **Bouros D, Pneumatikos I, Tzouveleki A.** – Pleural involvement in systemic autoimmune disorders. *Respiration* 2008; 75: 361-71.
3. **Kriegel MA, Van Beek C, Mostaghimi A, et al.** – Sterile empyematous pleural effusion in a patient with systemic lupus erythematosus: a diagnostic challenge. *Lupus* 2009; 18: 581-5.
4. **Pego-Reigosa JM, Medeiros DA, Osenberg DA.** – Respiratory manifestations of systemic lupus erythematosus: old and new concepts. *Best Pract Res Clin Rheumatol* 2009; 23: 460-80.
5. **Varda J Abraham D.** – Systemic sclerosis: a prototypic multisystem fibrotic disorder. *J Clin Invest* 2007; 117: 557-67.
6. **Yanaba K, Hasegawa M, Takehara K, et al.** – Comparative study of serum surfactant protein-D and KL-6 concentrations in patients with systemic sclerosis as markers for monitoring the activity of pulmonary fibrosis. *J Rheumatol* 2004; 31: 1112-20.
7. **McNearney TA, Revell JD, Fischbach M, et al.** – Pulmonary involvement in systemic sclerosis: associations with genetic, serologic, sociodemographic, and behavioral factors. *Arthritis Rheum.* 2007; 57: 318-26.
8. **Tillie-Leblond I, Wislez M, Valeyre D, et al.** – Interstitial lung disease and anti-Jo-1 antibodies: difference between acute and gradual onset. *Thorax* 2008; 63: 53-9.
9. **Chen IJ, Jan Wu YJ, Lin CW, et al.** – Interstitial lung disease in polymyositis and dermatomyositis. *Clin Rheumatol* 2009; 28: 639-46.
10. **Fujisawa T, Suda T, Nakamura Y, et al.** – Differences in clinical features and prognosis of interstitial lung diseases between polymyositis and dermatomyositis. *J Rheumatol* 2005; 32: 58-64.

11. **Ito I, Nagai S, Kitaichi M, et al.** – Pulmonary manifestations of primary Sjögren’s syndrome: a clinical, radiologic, and pathologic study. *Am J Respir Crit Care Med.* 2005; 171: 632-8.
12. **Parambil JG, Myers JL, Lindell RM, et al.** – Interstitial lung disease in primary Sjögren’s syndrome. *Chest* 2006; 130: 1489-95.
13. **Bodolay E, Szekanecz Z, Devenyi K, et al.** – Evaluation of interstitial lung disease in mixed connective tissue disease (MCTD). *Rheumatology* 2005; 44: 656-61.
14. **Kinder BW, Shariat C, Collard HR, et al.** – Undifferentiated connective tissue disease-associated interstitial lung disease: changes in lung function. *Lung* 2010; 188: 143-9.
15. **Quismorio FP Jr.** – Pulmonary involvement in ankylosing spondylitis. *Curr Opin Pulm Med.* 2006; 12: 342-5.
16. **Lee CC, Lee SH, Chang IJ, et al.** – Spontaneous pneumothorax associated with ankylosis spondylitis. *Rheumatology* 2005; 44: 1538-41.

