

Spontaneous Pneumothorax in a Case of Pulmonary Langerhans Cell Histiocytosis

Adrian CIUCHE^a, MD; Claudiu NISTOR^a, PhD; Daniel PANTILE^a, MR; Dragos MARIN^a, MR; Augustin TUDOSE^b, MD

^aDepartment of Thoracic Surgery

^bDepartment of Anesthesiology

“Dr. Carol Davila” Central Emergency University Military Hospital Bucharest, Romania

I undersign, certificate that I do not have any financial or personal relationships that might bias the content of this work.

ABSTRACT

Langerhans Cell Histiocytosis (LCH) is a rare disease involving clonal proliferation of Langerhans cells, abnormal cells deriving from bone marrow and capable of migrating from skin to lymph nodes. Clinically, its manifestations range from isolated bone lesions to multisystem disease. The authors present the case of 37 years old male, first diagnosed with Pulmonary LCH (PLCH) 9 years before current admission in thoracic surgery department, with left recurrent pneumothorax. The appropriate surgical resolution for this patient is thoracoscopic surgery with pleuro-pulmonary symphysis, resulting complete lung expansion. This procedure results in a significantly lower occurrence of subsequent same side pneumothorax, thus being the best choice for these patients.

Keywords: Langerhans Cell Histiocytosis, pneumothorax, thoracoscopic surgery

INTRODUCTION

Langerhans Cell Histiocytosis (LCH) is a disease which involves a clonal disorder of Langerhans cells, derived from the cells in the dendritic system. It can be classified as a unifocal or multifocal disorder (1) characterized by a proliferation of distinctive cells with ovoid, reniform, grooved

or highly convoluted nuclei and pale eosinophilic cytoplasm. Bone is the most frequent site of disease, although skin, lymph node, lung, and other sites may be involved (2,3). Lung involvement may occur as part of a multiorgan disease or as single system disease. The term “pulmonary” is used to refer to the disease that affects lung in either of two situations presented above (2).

Address for correspondence:

Adrian Ciuche, Department of Thoracic Surgery, “Dr. Carol Davila” Central Emergency University Military Hospital, Calea Plevnei, Sector 1, Bucuresti, Romania. Tel.: +40 21 319 30 51; Fax: +40 21 319 30 30.
e-mail: adi_ciuche@yahoo.com

Multisystem variants of the disease used to be known by a variety of names, such as: systemic histiocytosis X, Letterer–Siwe disease, and Hand–Schüller–Christian disease, while localized forms of LCH have previously been referred to as eosinophilic granuloma (2).

Little is known about the causation, natural history, treatment, and prognosis of Pulmonary Langerhans Cell Histiocytosis (PLCH) in adults (2). LCH usually affects children between 1 and 15 years old, with a peak incidence between 5 and 10 years. Among children under the age of 10, yearly incidence is thought to be 1 in 200,000; and in adults even more rare, in about 1 in 560,000. It has been reported in elderly but is vanishingly rare. It is most prevalent in Caucasians, and affects males twice as often as females.

Pulmonary LCH (PLCH) in adults is an uncommon disorder that occurs almost exclusively in smokers (3); the causation, natural history and prognosis are still to be accurately determined (2), also accurate epidemiological data are not yet available. Several studies were performed to determine the prevalence of PLCH stating that 0.5% of patients with diffuse infiltrating lung disease who were biopsied had LCH (4), while a more recent study performed in Belgium identified that 3% of patients with interstitial pneumonia were identified with LCH (5). A study of discharge diagnoses in Japan showed a crude prevalence of the disease estimated at 0.27 and 0.07 per 100,000 population in males and females, respectively (6).

The prevalence of PLCH is, however, probably underestimated because some patients exhibit no symptoms or experience spontaneous remission and histological findings are non-specific in the advanced forms (3). Few familial cases of LCH have been reported (7), but pulmonary disease occurs sporadically. PLCH has rarely been described in black patients and no accurate epidemiological data are available regarding racial differences. PLCH predominantly affects young adults, with a frequency peak at 20-40 years of age (3). Initial studies showed that PLCH was more predominant in males. Recent studies show a similar proportion of males and females, or even a slight predominance of females (3). These differences may reflect smoking habit changes over time. The most striking epidemiological characteristic of adult PLCH is that over 90% of patients are smokers. No other epidemiological factors associated with PLCH have been identified (3).

Histologically, PLCH begins as a proliferation of Langerhans cells along the small airways. The cellular lesions expand to form nodules as large as 1.5 cm, although most nodules are 1 to 5 mm (8).

Patients with PLCH present in a variety of ways. Up to one fourth of patients are asymptomatic at presentation. The most common presenting symptoms are nonproductive cough and dyspnea; constitutional symptoms (weight loss, fever, night sweats, and anorexia) occur in up to one third of patients. The presence of constitutional symptoms may lead to a search for an occult cancer. Hemoptysis occurs in less than 5 percent of patients, though occurrence of hemoptysis in an adult with PLCH should not be attributed to the underlying disease until other causes, such as bronchogenic carcinoma, have been excluded.

Chest pain occurs infrequently, but when it does occur, it is often pleuritic. Although chest pain may occur at the site of rib lesions, the cause of chest pain in PLCH is not always clear (9). Spontaneous pneumothorax is a recognized feature of PLCH, likely resulting from destruction of lung parenchyma with associated cystic changes (8). Spontaneous pneumothorax is sometimes responsible for chest pain (in 10–20% of cases). The occurrence of pneumothorax (16% of patients with PLCH (8) seems more common in young males; it may occur at any time during the course of the disease and may be bilateral and/or recurrent (up to 10% of patients with PLCH show recurrent pneumothorax), raising difficult therapeutic challenges (3,5,7). Pneumothorax should also be excluded in any patient complaining of increased dyspnea.

Other symptoms include pain due to involvement of bone; polyuria and polydipsia with diabetes insipidus related to hypothalamic involvement; rash secondary to cutaneous Langerhans cell histiocytosis; adenopathy due to superficial lymph-node involvement and abdominal discomfort due to infiltration of the liver and spleen (9). □

CASE REPORT

Our patient, P.F., male, 37 years old, smoker (15 pack-year), is admitted for medium effort dyspnea, fatigue and chest pain after a strong coughing effort.

From patient history we mention central diabetes insipidus (DI) which was diagnosed

over 10 years ago in treatment with desmopressin.

The patient was also known with a spontaneous pneumomediastinum, diagnosed 9 years before current admission. Except for the pneumomediastinum (Figure 1 a), the CT examination showed cavitated pulmonary nodules in both lungs (Figure 3 d). The radiologist suspected pulmonary fibrosis. At that time he was admitted in hospital and after several investigations (standard X-Ray, CT examination, association with diabetes insipidus) the patient was suspected of either PLCH – multisystemic disease with pituitary gland and lung involvement or pulmonary fibrosis. During these 9 years the patient followed the glucocorticoid therapy recommended after primary diagnosis, treatment which attenuated constitutional symptoms. Also, on doctors' recommendation, the patient ceased smoking and he was proposed for lung biopsy to determine histopathological diagnosis. The lung biopsy was not performed due to personal patient's reasons.

One month before current presentation, patient underwent a minimal pleurotomy for spontaneous pneumothorax (Figure 1 b and c).

Current X-Ray examination shows left partial pneumothorax with limited pleuro-pulmonary symphysis at left superior lobe level. Considering the recurrence of left pneumothorax after minimal pleurotomy, we decided that the patient will benefit from a more aggressive approach: thoracoscopic pleurodesis.

Before surgical intervention, patient underwent lung function tests. They showed mild mixed abnormalities. The results were as follows: FVC was 76% of predicted normal, FEV1 was 72% of predicted normal, FEV1/FVC ratio was 72%, and the residual volume/TLC ratio was 124% of predicted normal.

The surgical intervention has been performed using standard equipment for thoracoscopic surgery (cold light thoracoscopic tower); two ports were used for accessing the pleural cavity. After inspecting the pleural cavity and left lung – which presented multiple cysts (polycystic lung) we continued with the therapeutic procedure.

First, multiple lung biopsies have been taken for histopathological examination and Langerhans cell histiocytosis immunohistochemical studies, then the biggest air cysts have been li-

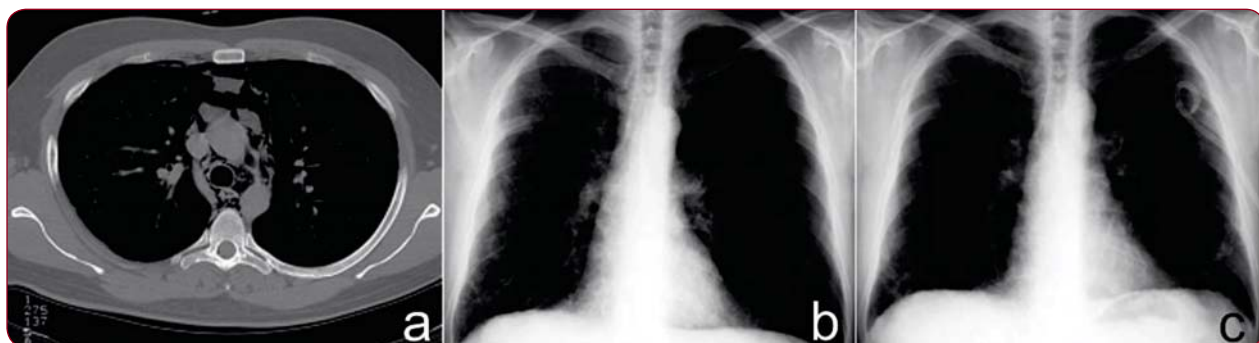

FIGURE 1. Preoperative aspects: A) pneumomediastinum (CT); B) left pneumothorax, before minimal pleurotomy (X-Ray); C) post minimal pleurotomy aspect: lung expansion (X-Ray).

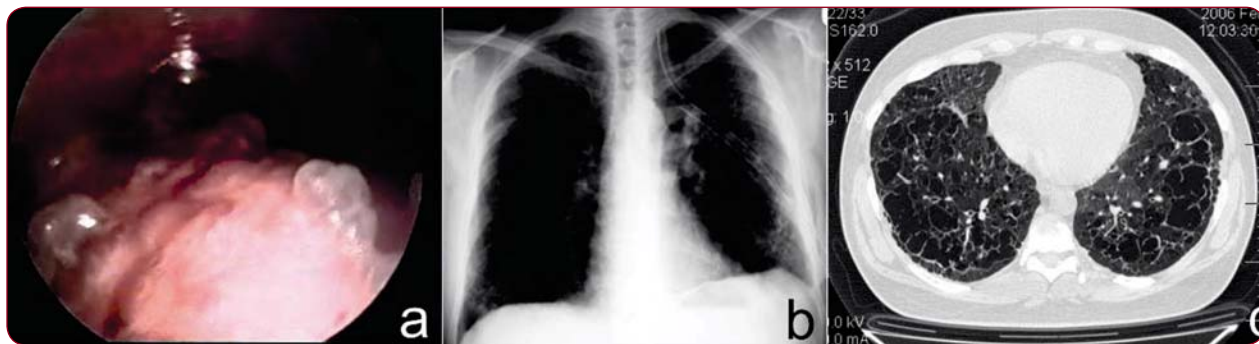

FIGURE 2. A) Intraoperative aspect (video); B) post-operative aspect: complete lung expansion (X-Ray); C) post-operative aspect – multiple cysts (CT).

gated to prevent the occurrence of pneumothorax. After carefully ligating the biggest cysts, pleural abrasion and chemical pleurodesis using penicillin were performed, maintaining one drainage tube for 24 hours as a witness for complete lung expansion. The instilled penicillin cause irritation between the parietal and the visceral layers of the pleura which closes off the space between them and prevents air from accumulating.

The patient was discharged three days after, completely asymptomatic and with radiologic proof of a complete lung expansion (Figure 2 b, c).

The biopsies taken were subjected to classic hematoxylin-eosin stain and also to immunohistochemistry test for CD1a and S100 identification (Figure 3 a, b, c). The biopsy report confirmed the suspected diagnosis: pulmonary Langerhans cell histiocytosis.

Three months after, the patient came for follow-up and the chest X-ray showed complete lung expansion, with no signs of pneumothorax recurrence, suggesting a good pleuro-pulmonary symphysis. The CT exam didn't show good news for the patient: ground-glass attenuation, adenopathy and extensive cystic changes involving the lungs peripheral areas. □

DISCUSSION AND CONCLUSIONS

These patients' evolution varies from spontaneous remission (associated with smoking cessation) to final stages of lung fibrosis with severe chronic respiratory failure – indication for lung transplantation.

Patients with PLCH are likely predisposed to develop pneumothorax based on destructive changes in the lung parenchyma resulting from their disease (8). Nodules with or without cavitation and cysts were present in the lungs

of our patient. Central cavitation in nodules can sometimes be traced to ectatic destroyed small airways (8), which were also seen in our patient. In addition, mediastinal emphysema (Figure 1 a; Figure 3 d), probably as a result of rupture of the microcysts, with air migrating into mediastinum along peribroncho-vascular sheaths (Maklin effect), was observed. As the disease advances, cystic spaces coalesce and bullas appear accompanied by increasing hyperinflation (8). Our patient has suffered multiple left pneumothorax episodes.

After nine years the compared CT examination showed evident worsening of lung disease with confluent lung cysts forming large air spaces which do not participate to gas exchange during the respiratory circle (Figure 2 c) and recurrent pneumothorax as a complication of ruptured cysts.

The variable natural history of PLCH and the lack of prognostic indicators complicate the management of this disorder. An essential part of treatment is considered to be smoking cessation, which leads to stabilization of symptoms in most patients and should be aggressively encouraged in all patients. A few reports also document objective radiographic and physiologic improvement in lung function after smoking cessation. Smoking cessation is also essential to prevent the occurrence or progression of other pulmonary conditions, such as chronic obstructive pulmonary disease (2).

Corticosteroids have been the mainstay of medical therapy for PLCH. Deciding when and how corticosteroids should be instituted is difficult, although clinicians must often treat patients who have progressive and symptomatic disease (3). Some reports suggest that corticosteroids may be of benefit in symptomatic PLCH complicated by pulmonary hypertension. In the absence of alternative effective

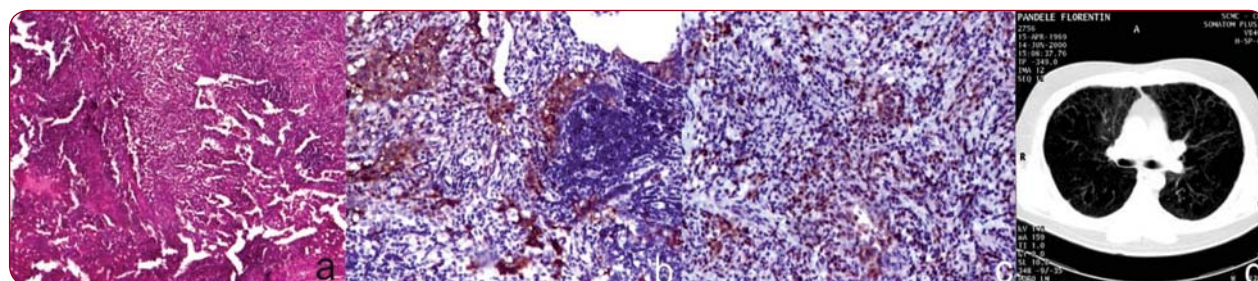


FIGURE 3. A) hematoxylin-eosin stain – pulmonary histiocytes infiltrates; B) CD1a+ - immunohistochemistry; C) S100+ - immunohistochemistry; d) first hospital admission CT scan, lung window: cavitated pulmonary nodules in both lungs.

therapies, it is reasonable to use corticosteroids for patients who have progressive disease or systemic symptoms; this treatment should generally be attempted only after smoking cessation (2,3).

Cytotoxic agents (vinblastine and, less often, methotrexate) are indicated in combination with glucocorticoid therapy in severe multisystemic LCH. There is no evidence that these agents are beneficial in adults with isolated PLCH. Although some agents have been shown to be useful in cases of refractory systemic LCH, an improvement in lung function in patients with PLCH has not been yet clearly demonstrated (3).

Regarding our patient, the surgical intervention performed after 9 years of glucocorticoid therapy was the appropriate therapeutic option for the given stage of disease, succeeding in realizing an efficient pulmonary symphysis which will prevent any recurrent pneumothorax. We decided to apply thoracoscopic mechanical and chemical pleurodesis because pleural abrasion and penicillin instillation induce different patterns of pleurodesis and a combination of each method generates synergy and produces a better pleurodesis (13). Also we avoided open-surgery parietal pleurectomy, thus the patient still being able to undergo a surgical intervention for lung transplantation when needed (parietal pleurectomy makes very difficult the surgical intervention for lung transplantation, but is not considered contraindication to lung transplantation (8)).

The natural history of the disease is widely variable and unpredictable in the individual patient. Up to 50% of patients experience a favourable outcome, either spontaneously (after smoking cessation) or with glucocorticoid therapy. Partial or complete clearance of the radiological abnormalities occurs, but lung function tests may still show obstructive dysfunction. About 10–20% of patients have early severe manifestations, consisting of recurrent pneu-

mothorax or progressive respiratory failure with chronic cor pulmonale. 30–40% of patients show persistent symptoms of variable severity with conversion of radiological nodules into thick-walled and then thin-walled cysts that remain stable over time. Despite the apparent quiescence of the disease in these patients with persistent stable cysts, LC granulomas may be present in the pulmonary parenchyma. Thus, long-term follow-up is mandatory and may detect exacerbation of respiratory dysfunction after many years, or, rarely, a relapse with recurrent nodule formation (3). Unfortunately, we lack the patient's feedback for more than 3 months after the surgical intervention and thus we do not have yet any information about the patient's evolution.

Factors reported to predict adverse outcomes include onset of PLCH at an old age, prolonged constitutional symptoms, recurrent pneumothorax, extrathoracic lesions (except for bone involvement, which has no bearing on the prognosis), diffuse cysts on imaging studies and severe pulmonary function abnormalities on diagnosis (particularly abnormalities in the FEV1 and FEV1/VC, and, to a lesser extent, in RV/TLC). None of these criteria is failure proof for predicting outcome in the individual patient. Severe pulmonary hypertension indicates a poor prognosis (2,3).

A high rate of primary lung cancer has been reported in patients with PLCH, with continued smoking being a risk factor; various other malignancies have also been found to occur at increased rates (3).

Although a complete guide in treatment of LCH and its complications is not yet available, we consider that the thoracoscopic pleural abrasion and penicillin instillation produced a good pleurodesis which should not allow another episode of pneumothorax. Also, given the disease prognosis, the thoracoscopic surgery will allow easier lung transplantation for the patient, when needed. □



REFERENCES

1. **Pinkus GS, Lones MA, Yamashiro S, et al.** – Langerhans Cell Histiocytosis – Immunohistochemical Expression of Fascin, a Dendritic Cell Marker. *Am J Clin Pathol* 2002; 118: 335-343.
2. **Vassallo R, Ryu JH, Colby TV, et al.** – Pulmonary Langerhans's-cell histiocytosis. *N Engl J Med* 2000; 26: 1969-1978.
3. **Tazi A** – Adult pulmonary Langerhans' cell histiocytosis. *Eur Respir J* 2006; 27: 1272-1285.
4. **Gaensler E, Carrington C** – Open biopsy for chronic diffuse infiltrative lung disease: clinical, roentgenographic, and physiological correlations in 502 patients. *Ann Thorac Surg* 1980; 30: 411-426.
5. **Thomeer M, Demedts M, Vandeurzen K** – Registration of interstitial lung diseases by 20 centres of respiratory medicine in Flanders. *Acta Clin Belg* 2001; 56:163-172.
6. **Watanabe R, Tatsumi K, Hashimoto S, et al.** – Clinico-epidemiological features of pulmonary histiocytosis X. *Intern Med* 2001; 40: 998-1003.
7. **Arico M, Haupt R, Russotto VS, et al.** – Langerhans cell histiocytosis in two generations: a new family and review of the literature. *Med Pediatr Oncol* 2001; 36: 314-316.
8. **Mendez JL, Nadrous HF, Vassallo R, et al.** – Pneumothorax in pulmonary Langerhans' cell histiocytosis. *Chest* 2004; 125:1028-1032.
9. **Howarth DM, Gilchrist GS, Mullan BPet** – Langerhans cell histiocytosis: diagnosis, natural history, management and outcome. *Cancer* 1999; 85:2278-2290.
10. **Favara BE, Feller AC, Pauli M, et al.** – Contemporary classification of histiocytic disorders. *Med Pediatr Oncol* 1997; 29:157-166.
11. **Colby TV, Lombard C** – Histiocytosis X in the lung. *Hum Pathol* 1983; 14:847-856.
12. **Friedman PJ, Liebow AA, Sokoloff J** – Eosinophilic granuloma of lung: clinical aspects of primary histiocytosis in the adult. *Medicine* (Baltimore) 1981; 60:385-96.
13. **Jin-Shing Chen, Wern-Cherng Cheng, Huang-Chun Lien, et al.** – Patterns, Effects, and Thoracic Volume Changes of Thoracoscopic Pleurodesis in Rabbits. *JSR* 2008; 147:34-40.