

A Rare Case of Benign Xanthogranuloma Located on the Uterine Cervix – a Case Report

Monica CIRSTOIU^{a,b}; Luminita Elena MITRACHE^{a,b}; Manuela POPA^{a,b};
Nicoleta Corina MEHOTIN^b; Maria SAJIN^{a,b}; Catalin CIRSTOIU^{a,b}

^a “Carol Davila” University of Medicine and Pharmacy, Bucharest, Romania

^b Emergency University Hospital, Bucharest, Romania

ABSTRACT

We report the case of a 44-year-old woman who presented with vaginal bleeding. Vaginal examination and colposcopy showed a tumor on the anterior lip of the cervix. Trans-vaginal sonography revealed a thickened endometrium with accentuated vascularization. Samples from the tumor and endometrium were collected by biopsy curettage. Histopathologic examination showed atypical hyperplasia of the endometrium and benign xanthogranuloma of the cervix. Therefore, surgical intervention was performed.

INTRODUCTION

Xanthogranuloma is a rare benign tumor that consists of numerous non-Langerhans histiocytes with a variable degree of lipidization (foamy cells). Other inflammatory cells, giant cells and fibroblasts may also be present (1).

There are two types of xanthogranulomas: juvenile and adult forms. Juvenile xanthogranulomas are usually described on the skin (2).

Adult xanthogranuloma is most frequently localized in the retroperitoneum, kidneys, lungs, mediastinum, stomach and breast (3,4). A case of vulvar involvement was reported in the literature, in 2002 (5).

In this paper, we are presenting a rare case of adult xanthogranuloma localized on the cervix. □

CASE REPORT

We report the case of a 44-year-old patient, who was admitted in our department with complaints of vaginal bleeding. The woman claimed that the symptoms commenced two years before and exacerbated progressively. Due to personal reasons she did not attend a gynecological examination in this period and also affirmed that she underwent the last pap smear and screening for common sexually transmitted infections 10 years before. The patient denied any previous medical condition or family history of malignancies or chronic diseases.

No abnormalities were noted during physical examination. However vaginal examination showed an approximately 2/1.5/5 cm tumor located on the anterior lip of the uterine cervix; vulva and vagina were grossly normal. We per-

Address for correspondence:

Monica Cirstoiu, Emergency University Hospital, 169 Splaiul Independentei, 5th District, Bucharest, Romania.
E-mail: luminita.mitrache@yahoo.com

Article received on the 21st of November 2014. Article accepted on the 19th of June 2015.

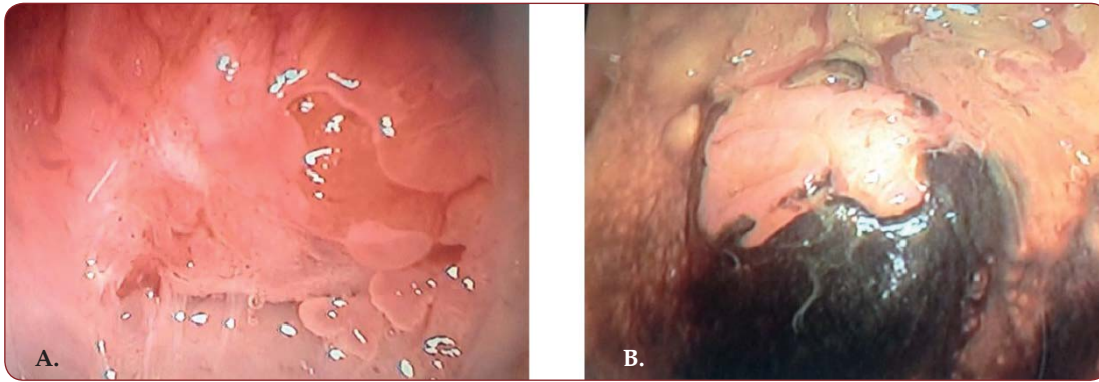


FIGURE 1. Aspects of the cervical tumor during colposcopy. **A.** Afixxation of three percent acetic acid. **B.** Afixxation of Lugol's solution.

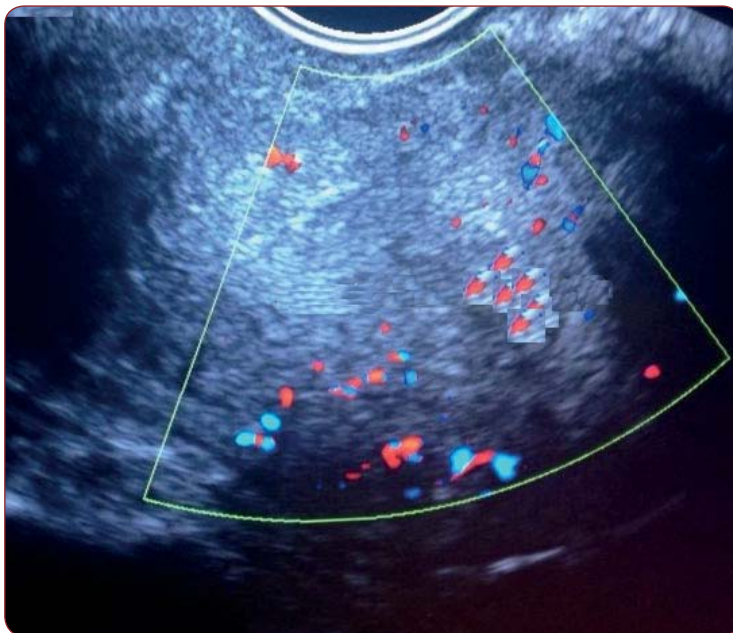


FIGURE 2. Echographic aspect of the uterine cavity - note the thickened endometrium with intense vascularization of during color flow Doppler.

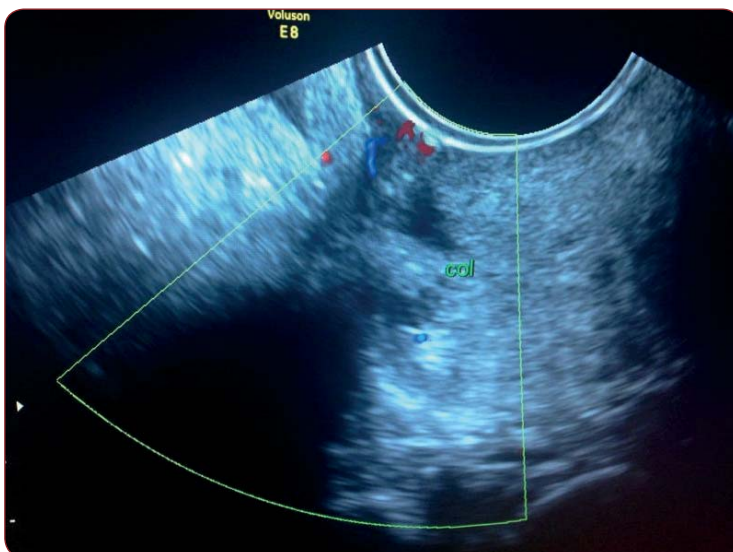


FIGURE 3. Echographic aspect of the cervix – note the vascularization of the tumor during color flow Doppler.

formed a colposcopy, during which we observed that the cervical tumor and the surrounding area on the anterior lip of the uterine cervix are aceto-white (affixation of three percent acetic acid), subsequently iodine-negative (affixation of Lugol's solution) (Figure 1); an increased vascular pattern was also noted in the area surrounding the tumor.

During trans-vaginal sonography we detected an anteverted uterus of normal dimensions, with a 13 mm thickened endometrium and accentuated vascularization during color flow Doppler. The cervical tumor was also recognized and during color flow Doppler we highlighted its vascularization.

We collected samples from the cervical tumor and its surrounding areas and performed biopsic curettage. Histopathological analysis of the fragments displayed complex atypical endometrial hyperplasia and cervical intraepithelial neoplasia 1 at the level of the squamous-columnar junction; an island of benign xanthogranuloma was also encountered.

Therefore, the patient was scheduled for the surgical intervention. Preoperative investigations were within normal ranges. Under general anesthesia, total hysterectomy with bilateral oophorectomy was performed. She recovered without complications and was discharged 5 days after surgery. □

DISCUSSION

Xanthogranuloma is a benign disorder characterized by formation of foamy cells clusters in the subepithelial connective tissue associated with inflammatory and giant cells (6). The presence of dense inflammatory infiltrates indicates a reactive xanthogranuloma (7,8). Considering the features of our case, there was

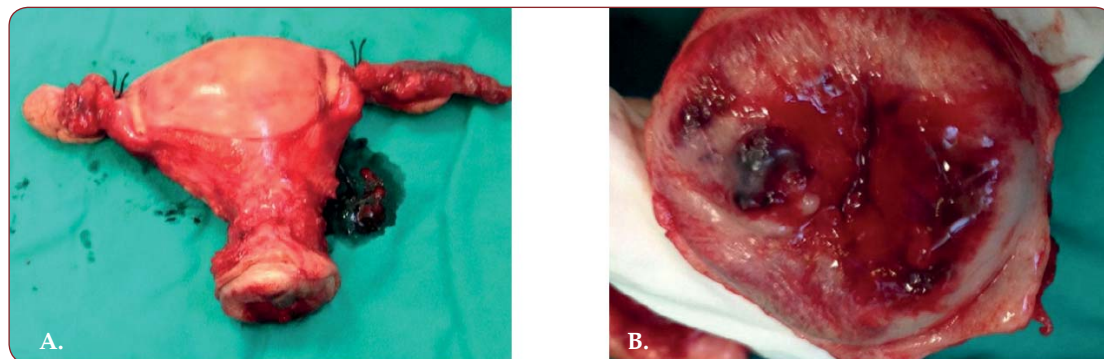


FIGURE 4. Postoperative macroscopic aspects of the extirpated viscera. A. Macroscopic aspect of the uterus B. Macroscopic aspect of the cervix.

no evidence of giant cells and we mention only a slight chronic inflammatory infiltrate. In conclusion, we are dealing with a non-reactive xanthogranuloma.

Xanthogranuloma of the female reproductive organs is a rare event. In the literature, involvement of the vulva, vagina and, rarely, endometrium was mentioned. Rare cases of reactive xanthogranulomas associated with dense inflammatory infiltrate were described on the cervix. Our case, besides its rare location on the cervix, was non-reactive and did not show remarkable inflammation.

Although the juvenile form is often considered to undergo regression, the adult xanthogranuloma is persistent in most of the cases (4).

Juvenile form of xanthogranuloma was described in patients with hematologic malignancies such as B-cell acute lymphoblastic leukemia (9).

It is important to consider the possibility of a coexistent malignancy of the reproductive organs. Histopathological examination, in our case, also revealed complex atypical endometrial hyperplasia and CIN 1 (cervical intraepithelial neoplasia - grade 1). In the literature, Russack and Lammers have reported six cases of xanthogranulomatous endometritis associated with endometrial carcinoma (10).

Association with malignant neoplasias of the same site is also sustained by the description of some gastric xanthogranuloma cases in association with early gastric cancer (3).

These features (the presence of atypical hyperplasias and other dysplastic changes associated with xanthogranulomas) may indicate the importance of the surgical procedures as prophylaxis. □

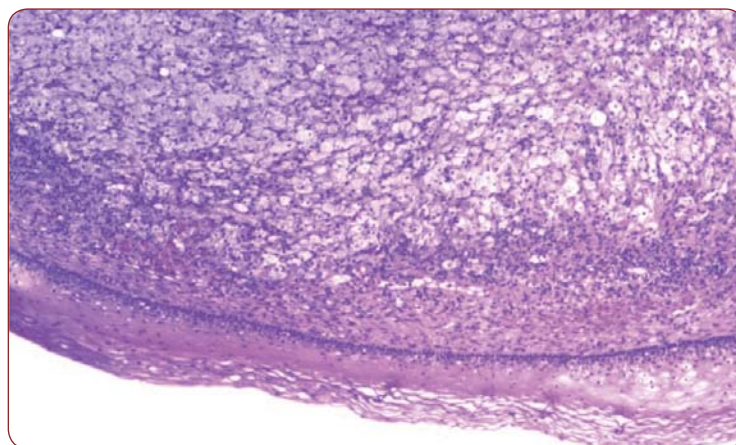


FIGURE 5. Microscopic aspect of the xanthogranuloma (foamy cells in the subepithelial connective tissue of the cervix).

CONCLUSION

Benign non-reactive xanthogranuloma of the cervix is a rare tumor of the female genital tract. We mention that no similar case was reported in the literature, so far.

Associated dysplastic changes may indicate a risk factor for malignancy development and stress the prophylactic importance of the surgical intervention.

Conflict of interests: none declared.

Acknowledgement: This paper is partly supported by the Sectorial Operational Programme Human Resources Development (SOPHRD), financed by the European Social Fund and the Romanian Government under contract number POSDRU 141531.

REFERENCES

1. **Sajin M, Costache A** – Curs de Anatomie Patologica, Editia a II-a revizuita si adaugita. Bucuresti: Editura Cermaprint, 2005.
2. **LeBoit PE, Burg G, Weedon D, et al.** – Pathology and Genetics of Skin Tumours. World Health Organization Classification of Tumours. Lyon: IACR Press, 2006.
3. **Kinoshita H, Yamaguchi S, Sakata Y, et al.** – A rare case of xanthogranuloma of the stomach masquerading as an advanced stage tumor. *World Journal of Surgical Oncology* 2011;9:67.
4. **Sung Ho Hwang, Eun Ju Son, Ki Keun Oh, et al.** – Bilateral Xanthogranuloma of the Breast Radiologic Findings and Pathologic Correlation. *J Ultrasound Med* 2007;26:535-537.
5. **Castilla EA1, Ormsby A** – Adult xanthogranuloma of the vulva: case report and review. *Pathology*. 2002;34:86-7.
6. **Kumar V, Abbas AK, Fausto N, et al.** – Robbins and Cotran Pathologic Basis of Disease, Eight Edition. Saunders Elsevier Inc., 2010.
7. **Kurman RJ, Ellenson LH, Ronnette BM** – Blaustein's Pathology of the Female Genital Tract, 6th edition. New York: Springer Science+Business Media, 2011.
8. **Nayak S, Acharjya B, Devi B, et al.** – Juvenile xanthogranuloma in an adult. *Indian J Dermatol* 2009;54(Suppl S)1:83-5.
9. **Shoo BA1, Shinkai K, McCalmont TH, et al.** – Xanthogranulomas associated with hematologic malignancy in adulthood. *J Am Acad Dermatol*. 2008;59:488-93.
10. **Narayan R, Mishra M, Mohanty R, et al.** – Xanthogranulomatous cervicitis. *Indian J Pathol Microbiol* 2008;51:458-9.

